




DIAGNOSIS HANDBOOK: FIBRODYSPLASIA OSSIFICANS PROGRESSIVA (FOP)



TIN
SOLDIERS
GLOBAL

EDUCATE · DIAGNOSE · REFER

Take a look inside - diagnosis is easy...

WHAT IS FOP ...

Fibrodysplasia Ossificans Progressiva = FOP

FOP is an ultra-rare genetic disorder where muscles, tendons, ligaments, and other connective tissues turn to bone. The extra (heterotopic) bone that forms is like normal bone. The heterotopic bone growth restricts a person's body movement, progressively over a lifetime. In short, people with FOP form a second skeleton which results in locked joints, making movement difficult or impossible and can leave a person permanently immobile.

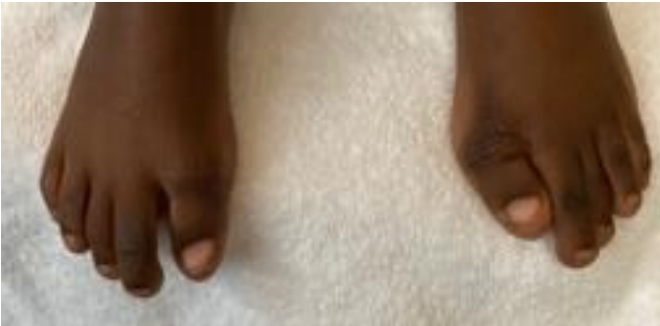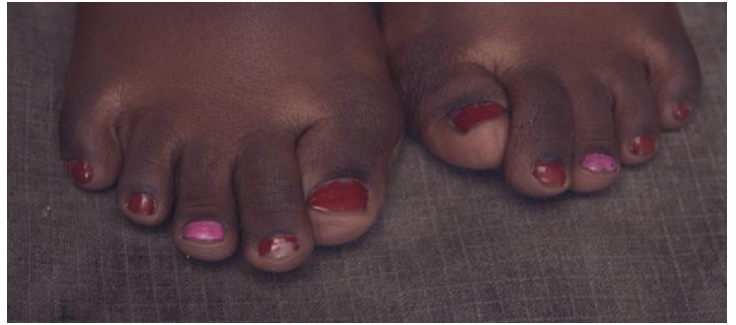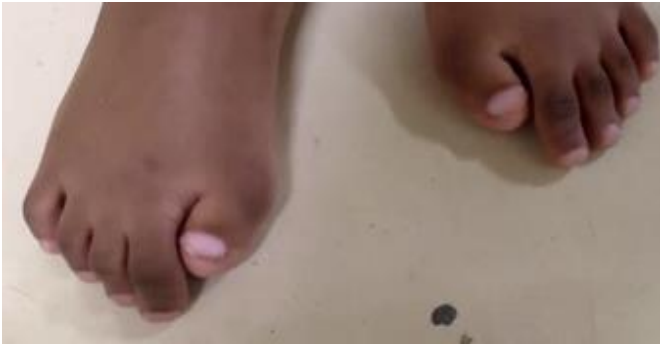FACTS ABOUT FOP:

- **People with FOP have malformed big toes and sometimes short thumbs**
- **FOP toes and thumbs may have a missing middle joint**
- FOP is an **ultra-rare genetic condition** with only about 900 known cases in the world: with an incidence rate of 1 in 1 million people
- FOP is **not contagious**
- FOP has **no ethnic, racial or gender patterns**
- FOP progresses in 2 ways – by presenting spontaneous flare-ups or as a result of trauma
- FOP is **misdiagnosed** over 90% of the time
- FOP is a debilitating disease that leads to **progressive immobility**
- Once heterotopic bone has formed, it **cannot be removed** because surgery causes more bone to develop
- Many people with FOP also have **hearing loss**
- Disease progression is **variable and hard to predict**
- FOP **does not affect intelligence**
- Heterotopic ossification forms in all skeletal muscle except the diaphragm, tongue, and extraocular muscles.
- FOP **has been around for many years** with the first note of it in a British medical journal nearly 300 years ago
- Some people with FOP live a **shortened life span**
- There are **likely thousands of people with FOP** that do not know what they have

WHAT TO LOOK FOR IN ORDER TO DIAGNOSE A PERSON WITH FOP...

#1. ARE THERE MALFORMED BIG TOES?

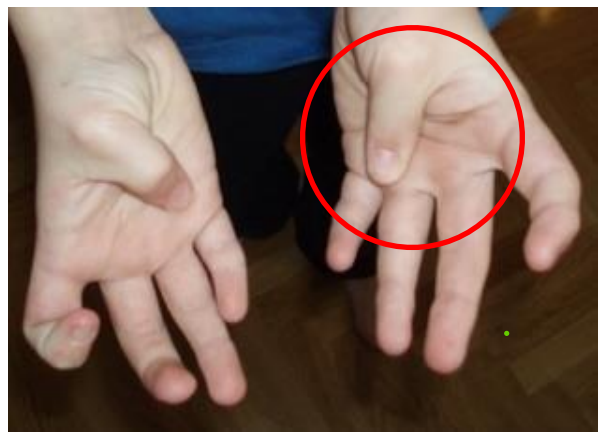
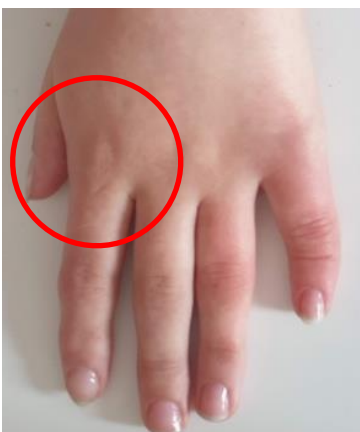- Both big toes must be malformed
- The toe malformation is present at birth
- The big toes may be missing the middle joint
- The big toes are often deformed in such a way that the big toe is turned inward toward the other toes



Examples of big toes that are short, big toes missing the middle joints and big toes pushed inward from malformation.

#2. DOES THE PERSON HAVE SHORT THUMBS?

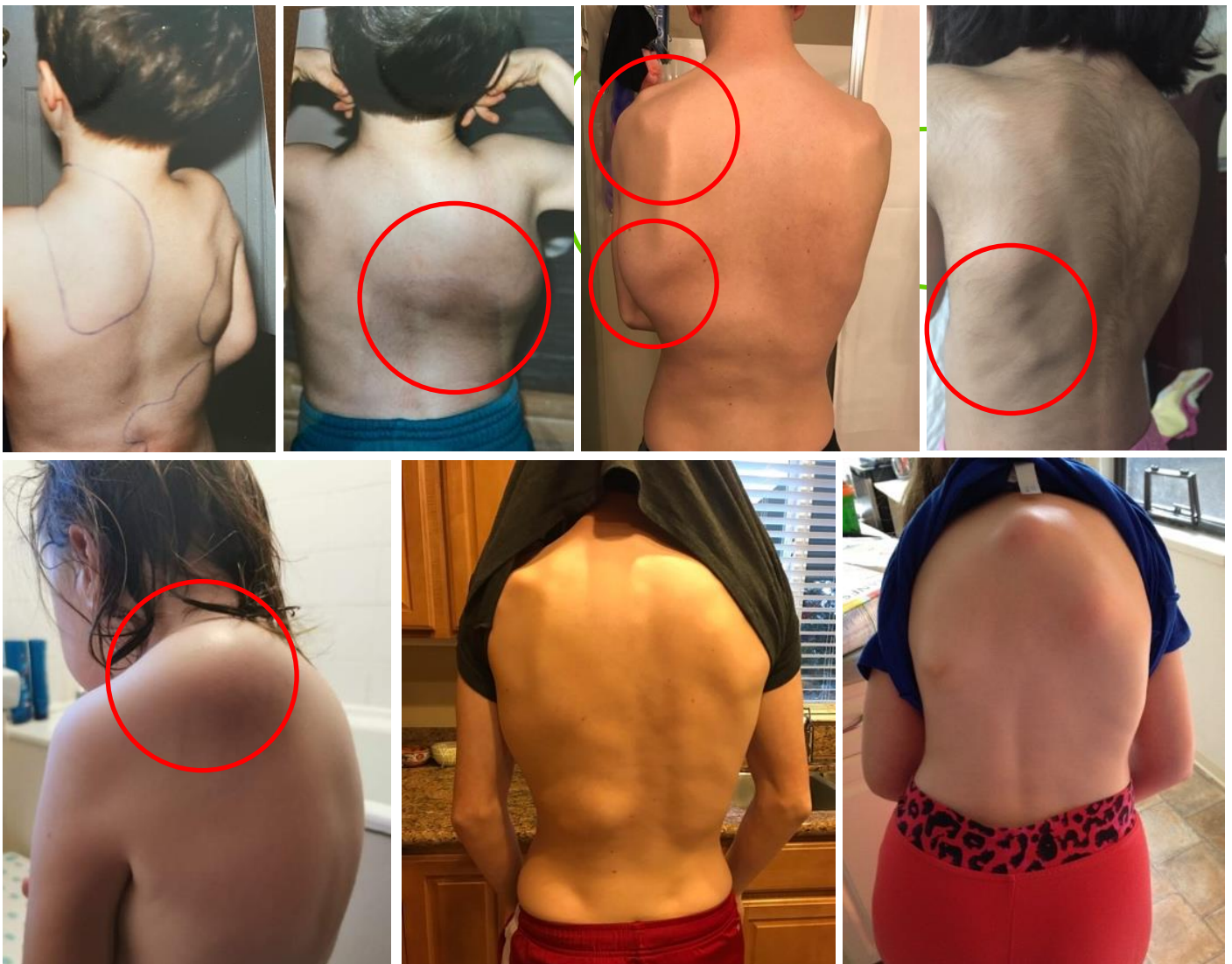- o Some people with FOP (~50%) can have short thumbs
- o The short thumbs may also have a missing middle joint



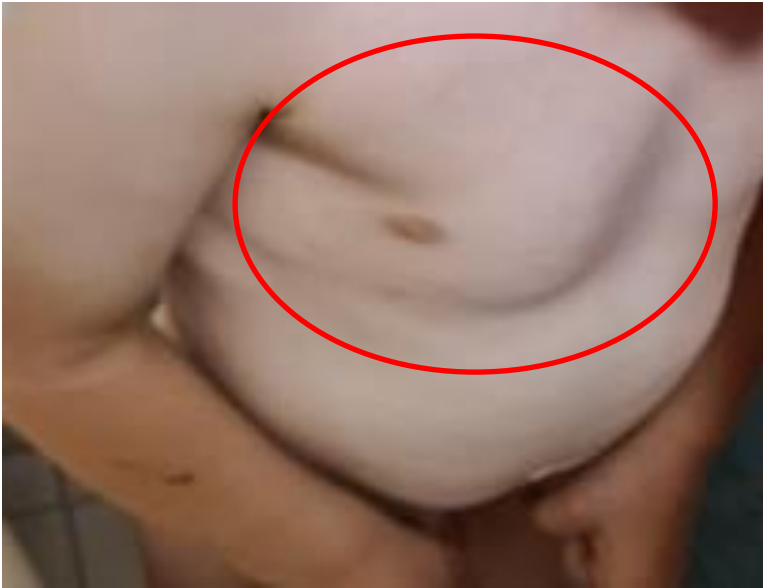Examples of short thumbs & thumbs missing the middle joint

#3. DOES THE PERSON CURRENTLY HAVE OR HAS THE PERSON HAD ANY HARD LUMPS ON THEIR BODY?

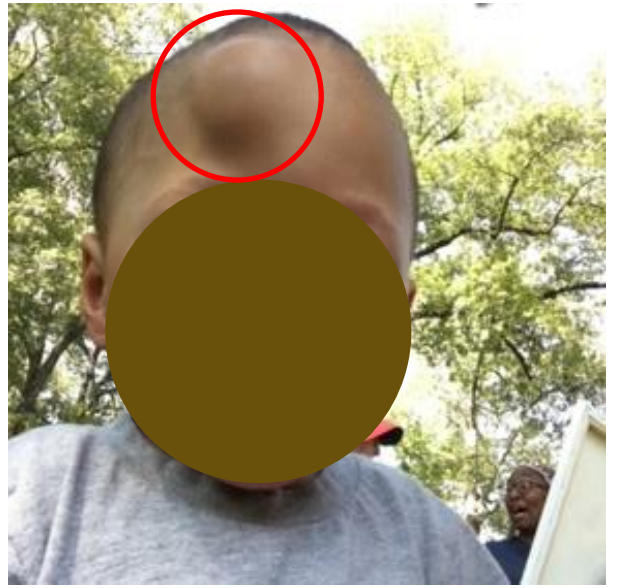- o Flare-up = swelling, edema, lumps
- o FOP flare-ups = edema can be hard, warm to the touch, and sensitive to the touch
- o Flare-ups can appear and change rapidly, often in a matter of hours.
- o Flare-ups can be mistaken as tumors, but tumors do not change and move around so rapidly.
- o Flare-ups can appear suddenly; they can also disappear quickly OR they can be present for a long period of time
- o Flare-ups in the scalp, neck, back, chest and arms are especially visible
- o Flare-ups in the hip and thigh area can be harder to see
- o Flare-ups may appear after some type of fall or minor/major injury



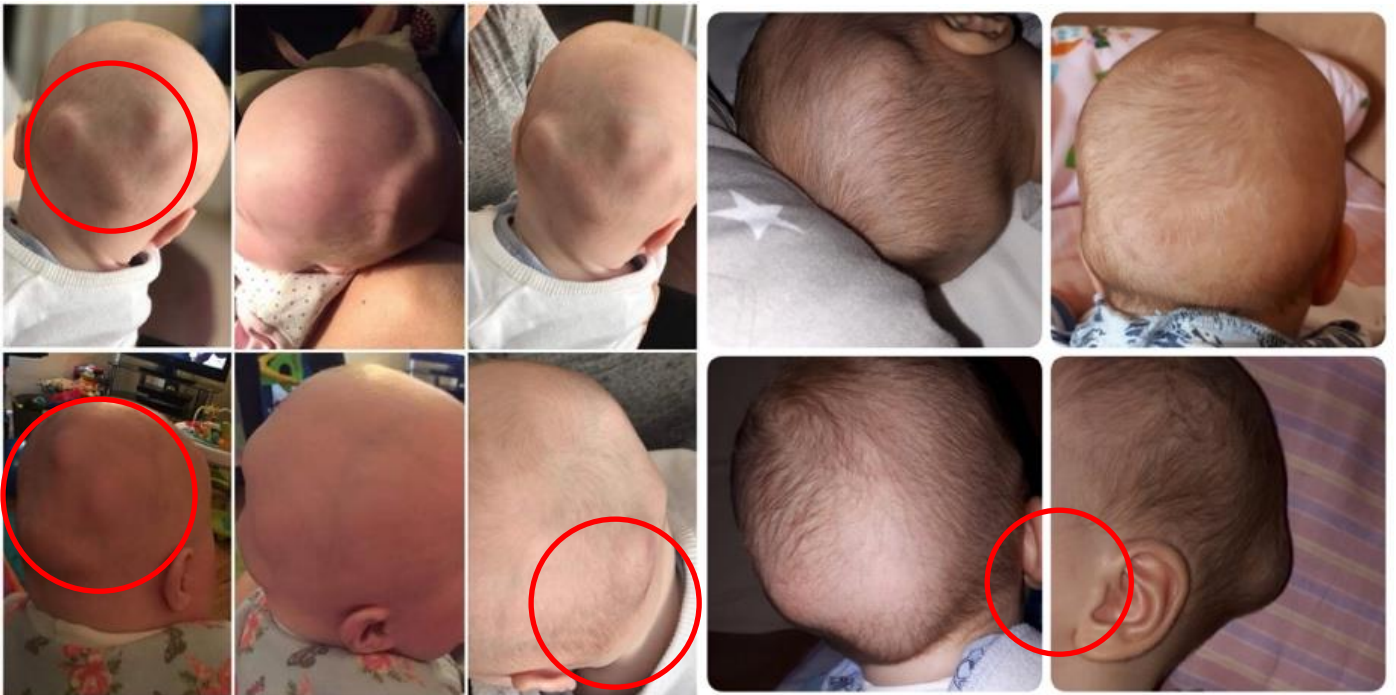Examples of flare-ups on the backs of children with FOP



Example of a chest flare-up




Example of a flare-up on the forehead



Examples of the flare-ups/lumps that often appear on a child's head who has FOP.

These lumps can come and go quickly and move around the head.

Heterotopic bone that forms on the head usually gets incorporated into the growing skull.



Examples of flare-ups in the neck area

FLARE/LUMPS FURTHER EXPLANATION:

A flare-up represents the early inflammatory phase of what often becomes heterotopic bone. In other words, “flare-ups” are often the first phase of heterotopic bone formation. A single “flare-up” may continue for as long as 6-8 weeks or longer. Hips flare-ups tend to last many months or even more than a year.

Multiple flare-ups may also occur during an active period of FOP. When a flare-up is in progress, joint stiffness may occur overnight. The stiffness comes from swelling and pressure inside the muscle during the earliest stages that precede new bone formation. While flares-ups are usually painful, the degree of pain varies among patients and among body locations. Many people find that the pain subsides when a flare-up is over.

Flare-ups can come and go quickly, as well as appear to move around the back and other parts of the body in a matter of days. It is difficult to know if the “migratory” nature of some “flare-ups” is due to a single flare that has moved around or the end of one flare-up and the beginning of another. In contrast, some flare-ups are present for weeks or even months.

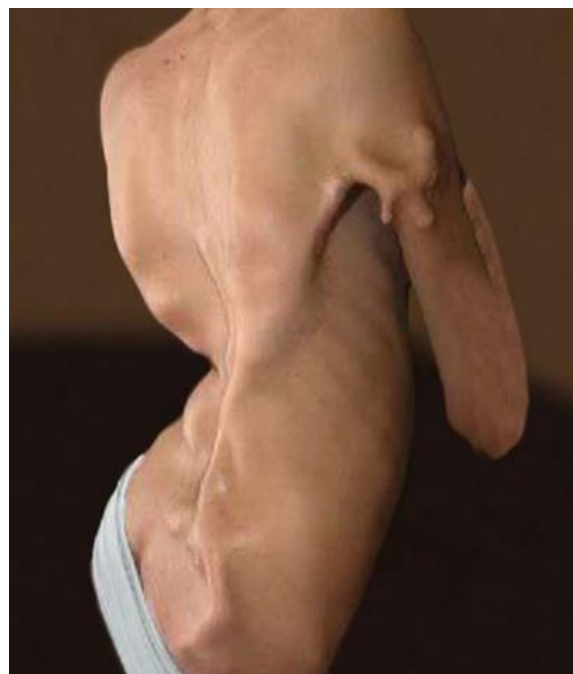A flare-up is not always easily seen or recognized as a flare-up. In large joints such as the hips it can be difficult to initially see swelling or edema, and the only symptom may be escalating pain in the groin region.

#4. DOES THE PERSON HAVE LIMITED MOVEMENT IN THEIR NECK, BACK, LIMBS OR JOINTS?

- o People with FOP form heterotopic/extra bone. That extra bone can limit the movement of the neck, spine, back, chest, shoulders, elbows, wrists, jaw, hips, knees, or ankles.
- o Heterotopic bone formation usually begins in the first decade of life and progresses episodically in characteristic anatomic patterns well into adulthood.



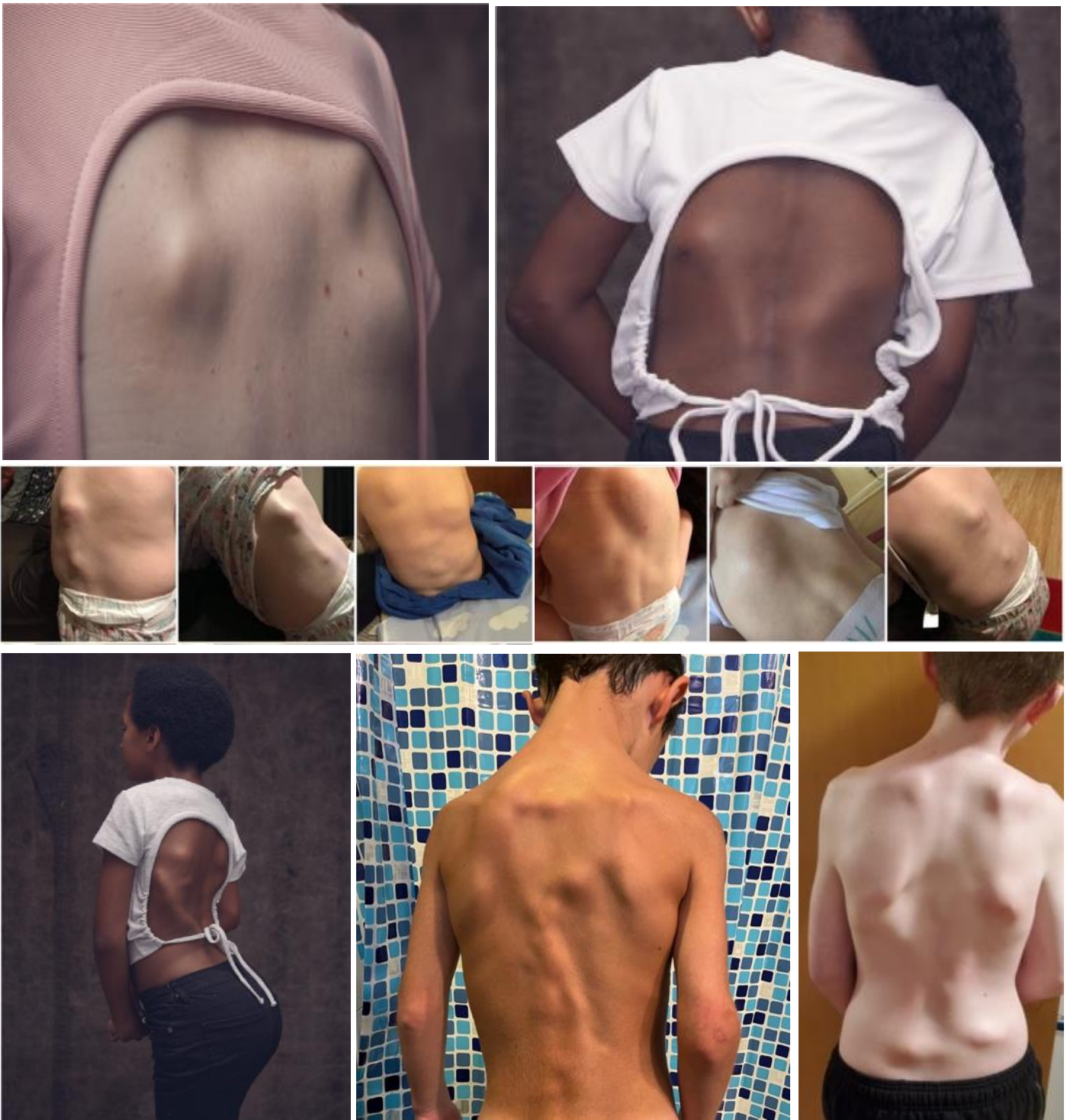
Photo of locked elbow from heterotopic



Example of extreme heterotopic bone

bone in the elbow joint

formation - patient had multiple surgeries



Photos of heterotopic bone formation on the back. Heterotopic bone can take any form but is more noticeable on the back because of relatively less subcutaneous fat compared to other areas.

LIMITED MOVEMENT/RESTRICTION FURTHER EXPLANATION:

Heterotopic bone growth restricts movement and usually follows the path of progression from the neck, spine, shoulders in the first decade of life followed by progression to the elbows, hips, knees, jaw, and ankles in the second decade of life.

TAKE ACTION TO CONFIRM A DIAGNOSIS:

STEP 1: DO NO HARM!

No biopsies; No surgeries! Efforts to remove heterotopic bone are fruitless and will cause more bone to grow.

NO intramuscular injections

NO stretching or pulling on any limbs on someone with FOP

Heterotopic bone growth can occur even with minimal trauma or without any warning.

AVOID TRAUMA TO THE BODY, IN ALL FORMS. FOP can easily be accelerated by even minor trauma to the body, so always **handle the patient gently and with special care.**

Some **common examples of trauma** are a bump, a biopsy, surgery, a fall, a mandibular block for dental work, over stretching of the jaw, or forced movement of locked limbs.

STEP 2: TAKE PHOTOS/VIDEO/GATHER INFORMATION

To confirm a proper diagnosis, **TIN SOLDIERS GLOBAL (TSG)** asks that you record the following and send to them by cell phone:

- o Get permission from the patient to share photos and information with the Tin Soldiers team. Tin Soldiers team will share these images with other physicians in their network to confirm or deny a diagnosis.
- o **Diagnostic photos** to be taken:
 1. Photos of both feet/toes against a light-colored background (like the photos of the toes displayed in this handbook)
 2. Photos of the hands – specifically the thumbs – take photo against a light-colored background
 3. Photos of any flare – ups or swellings
 4. Photos of any areas that look like heterotopic bone may have formed
 5. Photos of areas of the body that are stiff or may have body movement limitations
 6. Full body photo of patient clothed. Should wear gym pants or other suitable covering.
 7. Optional: Brief video(s) showing how the patient moves (walking or arms movement or limitations)
- o Complete the questions in the **Patient Diagnostic Referral Form** (see attached)

STEP 3: CONTACT TIN SOLDIERS...

TIN SOLDIERS GLOBAL is a nonprofit organization that has a global network of medical professionals that are well educated about FOP care. Our mission is to assist in the diagnosis of new patients across the globe so no one with FOP is ever left behind.

PLEASE contact **TIN SOLDIERS GLOBAL** as soon as possible for FOP expert support to ensure a proper diagnosis.

Email: info@tinsoldiers.org OR odette@tinsoldiers.org OR vanda@tinsoldiers.org

Whatsapp: 083 444 1880

The **Tin Soldiers** team is eager to support you by getting you connected to FOP medical professionals and giving you support for patient care. You as the medical professional, play a large role in securing a proper diagnosis.

Tin Soldiers Global will provide you with more information on how to support a patient once a clinical diagnosis has been confirmed. **Tin Soldiers Global** is connected to all national FOP organizations and international organizations that will be able to support a family in the journey with FOP. **Tin Soldiers Global** will be your partner in getting your patient the proper care and supporting you in the process.

WHAT YOU NEED TO SEND TO TIN SOLDIERS GLOBAL:

1. Photo of the **Patient Diagnostic Referral Form** filled out (see attached)
2. **Diagnostic photos** and videos

MUST READ MEDICAL HEALTH PRECAUTIONS ...

1. **A formal consult with FOP Expert Clinicians is strongly recommended. To facilitate this please contact the Tin Soldiers team.**
2. Avoid all IM (intramuscular) injections unless necessary for survival of the patient. IM injections may cause flareups and subsequent heterotopic ossification.
3. Stabilize & Treat: Venipuncture, subcutaneous & intravenous treatments are OK. Experienced staff and guided IV placement is highly recommended.
4. Peripheral IVs are permissible. Use smallest needle possible with brief tourniquet time. Avoid central venous access unless necessary for survival of the patient.
5. In case of major trauma, begin corticosteroids immediately Prednisone- 2 mg/kg/day (oral) or methylprednisolone 1.6 mg/kg/ day (IV) for 4 days. Evaluate for other potential causes of the flareup such as infection.
6. Intubation precautions: The cervical spine is often partially or completely fused from FOP. The jaw is likely limited in movement or functionally fused. Even if it is mobile, it is extremely susceptible to trauma. Do not passively manipulate. If noninvasive airway support is not possible, secure the airway with fiberoptic nasotracheal intubation by an experienced anesthesiologist. A surgeon should be immediately available to perform a tracheostomy if indicated. Steroids should be given if intubation is performed. Please refer to the [FOP Treatment Guidelines](#) for more.
7. Please note: No immunization should be given during a flareup. Intramuscular vaccines and the DTP (Diphtheria-Tetanus-Pertussis) vaccine should be avoided in all patients with FOP. If immunizations are given subcutaneously most other vaccines used in South Africa are recommended for individuals with FOP. Please consult the [FOP Treatment Guidelines](#) for advice regarding specific vaccines. If you are unsure, contact your FOP specialist doctor.

8. It is critical for people with FOP to have their family and caregivers accompany/provide care & advice for them in hospitals and appointments.

INFORMATION ON COVID-19 FOR THOSE WITH FOP

ICC = International Clinical Council on FOP

Visit iccfop.org for updated information on COVID-19 care for those with FOP.

ORAL HEALTH AND DENTAL PRECAUTIONS

1. It is essential that Mandibular Blocks/ Gow Gates injections are never done. These must be assiduously avoided as they can result in jaw ankylosis and closure.
2. Infiltration anesthesia is permitted for simple procedures. For any major dental procedure please follow recommendations in # 5 above.
3. Neck Mobility and other joint mobility must be considered when doing treatment and excess pressure and extended period of mouth opening during a procedure to be avoided. Please refer to Risk Management protocols as per the guidelines.
4. FOP Treatment Guidelines Atraumatic and Stabilization therapy should be initiated as soon as possible to limit the need for definitive restorative procedures. If unsure, please contact an Oral Health FOP specialist.

RESOURCES FOR LEARNING MORE:

Medical Treatment Guidelines for FOP go to: www.iccfop.org/guidelines/

To contact the **TIN SOLDIERS GLOBAL** Team email:

info@tinsoldiers.org OR odette@tinsoldiers.org OR vanda@tinsoldiers.org

For more information on the TIN SOLDIERS GLOBAL Program go to: www.tinsoldiers.org/

Information on FOP family support and FOP news visit: www.ifopa.com

***Thank you for taking the time to care and to play a significant role
in the diagnostic process.***

You are a Tin Soldiers Champion!

***We have lots of material available to view that tells the story of FOP
for access go to***

<https://www.youtube.com/channel/UCGm89tgRthpNzkodYapbTmw>

for additional printed materials please contact

info@tinsoldiers.org



TIN SOLDIERS VALUES

ENDING ISOLATION

To find people who are living in isolation, without a proper medical diagnosis, who are alone, scared and not knowing what to do

CARE

To first educate families and healthcare professionals on 'do no harm' and then connect them to the resources they need, for both medical and emotional support


LEAVE NO-ONE BEHIND

While finding people with FOP we also find others. We make sure we leave no one with a musculoskeletal condition behind. We connect them too!

Website: [Tinsoldiers.org](https://tinsoldiers.org)

Email: info@tinsoldiers.org OR odette@tinsoldiers.org OR vanda@tinsoldiers.org

Whatsapp: **083 444 1880**



**TIN
SOLDIERS
GLOBAL**

EDUCATE · DIAGNOSE · REFER

THE PATIENT DIAGNOSTIC REFERRAL FORM

If you think you have a potential FOP patient and would like to refer for an opinion please fill in the following questions:

1. Do you have the patients' permission for referral?
2. Do you have consent for sharing the patients images and contact details?
3. Why do you think patient has FOP?
4. Please describe any additional clinical features
5. Has the patient had any recent treatments ie. Biopsy, scan etc. if so, what
6. Please send photos of: toes, back, any areas of limitation or lumps
7. Please send any available radiology images, please include x-rays of the toes

